

Research Article

Surgical Treatment of Zenker's Diverticulum In Older Patients

Janusz Włodarczyk ^{1,*}, Alicja Włodarczyk ²

1. Department of Thoracic and Surgical Oncology, Jagiellonian University Collegium Medicum, John Paul II Hospital, Cracow, Poland; E-Mail: jr.wlodarczyk@gmail.com
2. Jagiellonian University Collegium Medicum, Faculty of Medicine, Cracow, Poland; E-Mail: alicja.wlodarczyk@student.uj.edu.pl

* **Correspondence:** Janusz Włodarczyk; E-Mail: jr.wlodarczyk@gmail.com

Academic Editor: David G Smithard

Collection: [Dysphagia in the Elderly](#)

OBM Geriatrics
2021, volume 5, issue 3
doi:10.21926/obm.geriatr.2103179

Received: October 26, 2020
Accepted: August 10, 2021
Published: August 18, 2021

Abstract

Zenker's diverticulum is a cause of benign dysphagia. The main symptoms include dysphagia and regurgitation and require diagnostics to exclude neoplastic disease. Surgical treatment is recommended for symptomatic patients. The methods of treatment include endoscopic and open transcervical techniques. Thirty-eight patients treated using the open technique between 2000 and 2020 were analyzed. Patients were qualified for the procedure after a complete diagnosis that excluded the neoplastic process. All patients were assessed for the degree of dysphagia, weight loss, and comfort after surgery. All patients underwent a transcervical diverticulum resection with a myotomy of the cricopharyngeal muscle for a minimum length of 3 cm. After surgery, the patients showed improvement in swallowing and could be fed orally; their diet was complete. One patient (2.6%) had an esophageal fistula which was successfully treated conservatively, two patients (5.2%) required reoperation due to postoperative bleeding, and two patients (5.2%) experienced temporary laryngeal nerve palsy. One patient required retreatment due to recurrent diverticula 20 months after the surgery. There was no death in the perioperative period. 'Very good' long-term functional results were obtained in 27 (71.1%) patients, 'good' in eight (21.1%), and 'bad' in three (7.9%).



© 2021 by the author. This is an open access article distributed under the conditions of the [Creative Commons by Attribution License](#), which permits unrestricted use, distribution, and reproduction in any medium or format, provided the original work is correctly cited.

The traditional open technique of treating cervical diverticula of the esophagus is safe for older patients, has an acceptable percentage of postoperative comorbidity, and yields good functional results.

Keywords

Dysphagia; Zenker's diverticulum

1. Introduction

A cervical diverticulum of the esophagus represents a rare disease, with an incidence of 2/100,000 cases in the general population [1]. It affects women more frequently than men [1]. The condition was named Zenker's diverticulum after the German pathologist, who was the first to accurately describe the physiopathology of the condition, although it was first identified many years before that by Ludlow [2, 3]. It is believed that Zenker's diverticula are caused by a dysfunction of the pharyngolaryngeal region that leads to an outpouching of the mucosa of the posterior pharyngeal wall. Although the etiopathogenesis of the disease is still unclear, it is associated with impaired relaxation of the upper esophageal sphincter and disrupts normal swallowing. The diverticulum occurs when increased pressure during swallowing leads to esophageal mucosa and submucosa herniation into the Killian's triangle [4-6]. The disease usually affects individuals above 70 years.

One of the surgical treatment options is the classical technique of diverticular resection, diverticulopexy, or plication with or without myotomy. Myotomy is a standard surgical management method proposed by Belsey in the 1960s [7]. Another management method is endoscopic treatment, which consists of Z-POEM and transection of the septum between the diverticulum and the esophagus using a stapler (mechanical sutures), a laser, or an ultrasonic scalpel. We performed these endoscopic procedures by fiberoscopy or rigid endoscopy.

In this paper, an analysis of the treatment of older patients using a classical technique — transcervical diverticular resection with myotomy — was performed. Surgical treatment of older patients is always challenging for the treating team. As a part of the analysis, complications following open surgical treatment of esophageal diverticula, as well as the comfort of the patients, were assessed.

2. Patients and Methods

Patients underwent surgical intervention for a cervical esophageal diverticulum between 2000 and 2020 in the Department of Thoracic Surgery and were subjected to a retrospective analysis.

2.1 Patients

Pre-surgery, all the patients underwent a chest X-ray, contrast-based examination of the esophagus (Figure 1), and esophagoscopy chest computed tomography scan (Figure 2). Bronchoscopy was performed to assess vocal cord functions in patients who were additionally eligible for resection of nodular goiter and in those with phonation disorders while speaking. Patient

eligibility for surgical treatment was based on the size of the diverticulum and any accompanying signs and symptoms (dysphagia, regurgitation, recurrent pneumonia, weight loss, or recurrent diverticulum following surgery). The primary indication for surgical treatment was dysphagia, which prevented oral feeding and was assessed before and after surgery based on a four-grade scale [8]:

- 0 - no dysphagia
- 1 - swallowing of a semi-liquid diet
- 2 - swallowing of a liquid diet
- 3 - dysphagia to liquids and saliva

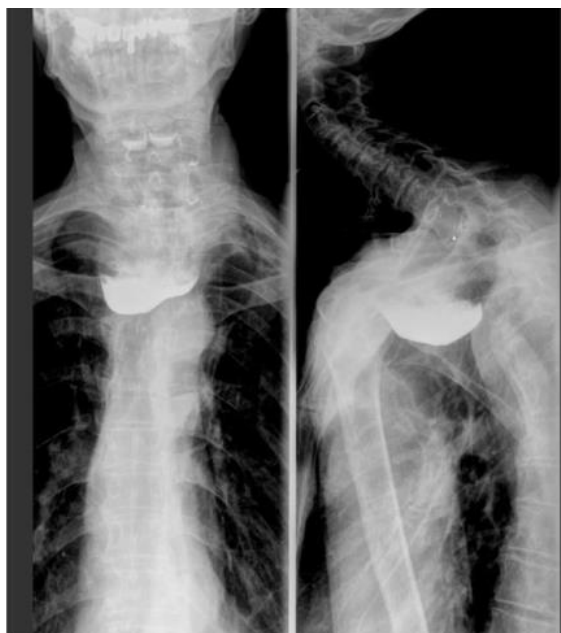

Figure 1 Contrast examination of the esophagus revealed the presence of a large Zenker's diverticulum causing dysphagia.

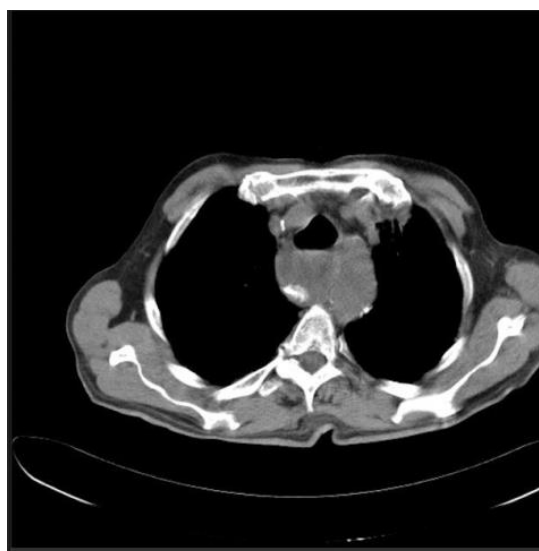


Figure 2 Zenker's diverticulum from the same patient is shown using computed tomography.

2.2 Methods

The patients were qualified for classic transcervical diverticulum resection. An incision was made laterally in the neck, along the sternocleidomastoid muscle; the platysma was dissected, and the omohyoideus was exposed and dissected; the pharyngoesophageal region was exposed. The neurovascular bundle was gently retracted, and the thyroid gland was dissected to expose the diverticulum. The recurrent laryngeal nerve was exposed. In patients with indications for thyroid lobectomy, the classical method of single-lobe resection was applied. The diverticulum was dissected, its neck was displayed and excised using mechanical sutures (TA-30 Ethicon, USA; Endo-GIA 45 Auto-Suture, USA) or managed with PDS 000 manual sutures, leaving a 1-cm margin to protect the patient from postoperative esophageal stricture. Myotomy was initiated by transecting the cricopharyngeal muscle below the lower part of the resected diverticulum, which was extended to the muscular layer of the esophagus for a section of at least 3 cm. An endoscopic procedure was then performed to assess the tightness of the suture line. Performing postoperative wound drainage and the use of a gastric tube was at the operator's discretion.

2.3 The Postoperative Period

2.3.1 Nutrition

During the first 24 hours after surgery, the patients with gastric tubes were tube-fed, while patients without tubes were initially administered clear liquids orally. Then, a diet comprising liquid and minced food was gradually introduced over the next few days of hospitalization. A minced diet was recommended to all the patients for 14 days after discharge from the hospital.

A contrast examination of the esophagus or esophagoscopy was routinely performed on Day 4 or 5 after the surgery.

2.3.2 Follow-Up

The patients' quality of life was assessed for 30 days after surgery, and then once every three months in the first year and once a year in the subsequent years. If an on-site follow-up appointment was not feasible, the patients were interviewed over the phone. During each follow-up visit, the swallowing function in dysphagia, the overall condition, and the level of comfort were assessed using the Visick scale (9).

2.3.3 Statistical Analyses

Statistical analyses were performed using the software package STATISTICA 10 PL (StatSoft, Tulsa, OK, USA). Differences among and between patients were determined by performing Gehan-Wilcoxon, Kruskal-Wallis, and Mann-Whitney tests. To determine pairwise differences between ordinal values (categorical data), Fisher's test was used. Values of $p < 0.05$ were considered to indicate statistically significant differences among /between groups.

3. Results

Thirty-eight patients were operated on at the Department of Thoracic Surgery; 28 (73.1%) men and 10 (26.9%) women, aged 75 to 88 years (mean age of 78 years), had participated in this study (Table 1).

Table 1 Clinical characteristics of the patients.

Patients	Results
Age [years]	
Median	78
Range	75-88
Sex, [n (%)]	
Male	28 (73.1)
Female	10 (26.9)
ASA class	38
ASA II	23
ASA III	15
BMI	
Mean	20.8
Range	18.3-28.2
Duration of symptoms [months]	
Median	22.6
Range	10-48
Size of diverticulum [cm]	
Mean	4.9
Range	3-8
Comorbidities	54
Hypertension	25
Diabetes	9
Cardiovascular insufficient	9
Coronary insufficient	2
Post-myocardial infarction status	2
Mental dysfunction	4
Dementia	2
Stroke	1

BMI-body mass index

ASA-American Society of Anesthesiologists

3.1 Symptoms

The most common symptoms among the patients were dysphagia regurgitation and weight loss, which became more pronounced over 10 to 48 months (mean: 22.6 months) (Table 2). During preoperative evaluation, the degree of dysphagia was 2.25 (range: 2-3) and after surgery it was 1.4 (range: 1-2) ($p = 0.002$). Relief from dysphagia was observed during postoperative evaluation in 35

(92.1%) patients. The loss of body weight, observed in 18 (47.3%) patients, ranged from 4 to 14 kg (average: 5.7 kg). Most of the lost weight was regained to pre-disease levels after surgical treatment ($p = 0.003$).

Table 2 Surgical complications according to the Clavien-Dindo classification [9].

Grade	Number of patients (%)	Definition
I	9 (23.7%)	Temporary laryngeal nerve palsy - two patients; urinary tract infection - one patient; wound infection - two patients; temporary mental disorder (postoperative delirium) - four patients Any deviation from the normal postoperative course without the need for pharmacological treatment or surgical, endoscopic, or radiological interventions The allowed therapeutic regimens include antiemetics, antipyretics, analgesics, diuretics, electrolytes, as well as, physiotherapy. This grade also includes wound infections opened at the bedside.
II	1 (2.6%)	Esophageal fistula - conservative treatment Pharmacological treatment that requires drugs, besides those allowed for Grade I complications Blood transfusions and total parenteral nutrition are also included
III	0	Surgical, endoscopic, or radiological intervention required
IIIa	0	Intervention without general anesthesia
IIIb	3 (7.9%)	Reoperation due to postoperative bleeding Intervention under general anesthesia
IV		Life-threatening complication (including CNS complications)* requiring IC/ICU-management
IVa	0	Single organ dysfunction (including dialysis)
IVb	0	Multiple organ dysfunction
V	0	Patient death

*brain hemorrhage, ischemic stroke, subarachnoidalbleeding, but excluding transient ischemic attacks (TIA); IC: Intermediate care; ICU: Intensive care unit.

3.2 Surgical Treatment

3.2.1 Patients

Patients with diverticula (3 to 8 cm in size; mean: 4.9 cm) were eligible for surgical treatment. Primary diverticulectomy was performed in all patients, three of whom underwent simultaneous lateral single-lobe resection due to an accompanying nodular goiter. In 30 (78.9%) patients, the diverticulum was removed using a stapler; the operative bed was sutured manually (Vicryl 000 or PDS 0000) in eight patients. The tightness of the suture line was confirmed by a contrast esophagram and endoscopy in all patients. One patient was operated on again after 20 months due to a recurrent diverticulum, and recurrence was suspected in another patient. No deaths were reported during the post-surgical period.

The median operative time was 167 minutes, with a range of 118-201 minutes. Perioperative complications were assessed according to the Clavien-Dindo classification (Table 3) [9].

Table 3 Symptoms of Zenker’s diverticulum in patients before and after surgery.

Symptoms	Prior surgery	After surgery
Dysphagia	18 (47.4%)	3 (7.9%)
Regurgitation	12 (31.6%)	3 (7.9%)
Halitosis	17 (44.7%)	8 (21%)
Mean weight loss [kg]	-5.8	0
Gurgling sounds	9 (23.7)	2 (5.2%)
Globus	4 (10.5%)	4 (10.5%)
Aspiration pneumonia	4 (10.5)	0

3.3 Major Perioperative Complications

One patient (2.6%) demonstrated symptoms of fistula. As the presentation was oligosymptomatic (lack of fever, drainage of approximately 10-20 ml/24 h, and an absence of mediastinal leakage), the patient was qualified for conservative treatment. Antibiotic therapy and parenteral nutrition were initiated. The fistula was treated eight days after onset (Grade II). A contrast follow-up examination was performed, and no signs of esophageal stricture were observed. The long-term follow-up did not reveal any recurrence of esophageal stricture.

One patient (2.6%) experienced postoperative bleeding and required double re-surgery, and another (2.6%) patient was operated on again due to hematoma (Grade IIIb).

3.4 Minor Postoperative Complications

Two patients (5.2%) experienced vocal cord paralysis, which was resolved at months 3 and 4 following surgical treatment, as confirmed by bronchoscopy. Postoperative wound infection was observed in two cases (5.2%), four patients (10.5%) manifested symptoms of postoperative psychosis, and urinary tract infection was reported in one patient (2.6%) (Grade I).

3.5 Late Complications

A recurrent diverticulum was observed in one patient (2.6%) 20 months after surgical treatment. It was associated with an excessive margin of the diverticulum resection. A myotomy was performed following transection of the cricopharyngeal muscle at 2 cm. After the treatment, the patient underwent a 23-month follow-up. The patient showed no signs of dysphagia and was comfortable with oral nutrition.

Impaired swallowing of solid food after treatment was observed in another patient, with good tolerance to a liquid diet and no aspiration. Endoscopic and radiographic examinations did not reveal a recurrent diverticulum. Conservative management was recommended.

The median length of stay at the hospital after surgery was 8.7 days (range: 6-12 days).

In the postoperative period, 38 patients were followed up for 1 to 21 months (mean: 14 months, median: 9 months). Postoperative comfort was assessed using the Visick score [10]. A ‘very good’

score was achieved for 27 patients (71.05%), a 'good' score for eight (21.05%), and a 'bad' score for three (7.89%) patients.

4. Discussion

A cervical diverticulum of the esophagus is a benign disease resulting from dysfunction of the cricopharyngeal muscle and relaxation of the posterior pharyngeal wall, leading to a progressive protrusion of the mucosa through areas of decreased resistance (i.e., Killian dehiscence) [6, 8]. The treatment options include a traditional open surgical approach and endoscopic methods. Due to rapid advancements in endoscopic techniques and their effectiveness, they are the preferred treatment methods and the gold standard of management [11].

Among patients with a Zenker's diverticulum, the dominant symptom is dysphagia, which causes regurgitation, cough, and can lead to aspiration pneumonia. It is estimated that approximately 30% to 40% of older patients experience aspiration [12]. Dysphagia, cough, and recurrent pneumonia lead to a lower quality of life for the patients. Surgical treatment is an effective management option, as it enables normal oral nutrition.

The choice of surgical technique for the treatment of diverticula is still an unresolved question. Traditional surgical treatment has various forms. Open approaches include diverticular resection with myotomy, diverticulum suspension, or invagination (imbrication). The size of the diverticulum and the surgeon's experience should be considered while choosing between an endoscopic or open approach for the treatment. Gutschow et al. proposed myotomy only, diverticular suspension and myotomy, and diverticular resection with myotomy for diverticula that are <1 cm, 1 to 4 cm, and over 4 cm, respectively. The authors did not recommend diverticular imbrication due to the higher rates of recurrence [13]. Both Gutschow et al. and Bonavina et al. achieved successful open treatment outcomes in groups of patients with medium-sized diverticula, compared to the outcomes of the treatments with the endoscopic approach [13-15].

A mandatory component of surgical management is myotomy [7]. Despite the approved cervical myotomy standard, but its length is not standardized and ranges from 2 to 6 cm. Lerut et al. had suggested that the size should be 5 cm [16]. On the other hand, Colombo-Benkemann et al. had suggested that myotomy should be performed specifically in patients with hypertrophy of the cricopharyngeal muscle [17].

Myotomy is necessary to restore normal swallowing function when it is impaired due to abnormal relaxation of the cricopharyngeus. Swallowing is also affected by the elevation of the pharyngolaryngeal complex and the pharyngeal pressure, which allows clearance of the bolus through the open superior pharyngeal constrictor, and has been confirmed by manometric investigations [18]. Forgoing myotomy entails a risk of fistula, aspiration pneumonia, and recurrent diverticulum [12-15].

Surgical treatment outcomes are influenced by the knowledge of the pharyngolaryngeal anatomy, a precise surgical diverticular dissection, and myotomy [13]. The surgical approach is associated with relatively low rates of complications, which are estimated to be approximately 10.5% on average, although the values range widely (from 0% to 46%) in the literature [19]. This treatment method is characterized by low mortality, which is estimated to be 0.6% (ranging from 0.2% to 3.0%) [14, 15]. Major complications following open surgery include vocal cord paralysis, which might be temporary (3.6%) or permanent (1.6% to 3.3%) [14, 19]. Another complication of

diverticular resection is the esophageal fistula along the suture line. It is estimated to occur in approximately 3.3% of the cases, although in some reports, it is estimated to be as high as 5.3%; additionally, there is an associated risk of myotomy not being performed [19, 20]. The esophageal fistula requires close monitoring, as it poses a risk of descending mediastinitis, which is estimated to have a rate of approximately 0.2% [18]. A precise clinical evaluation of the patients is required, and they need to undergo a computed tomography scanning of the chest for mediastinal assessment. An effective treatment option is usually conservative management, while surgical intervention is necessary for a small group of patients [18].

A recurrent diverticulum is a rare, late, postoperative complication, occurring in approximately 0% to 22% of cases [16, 21, 22]. Its causes are not well-known, but among them might be an incomplete myotomy; this can be diagnosed by dynamic contrast radiography, by which a cricopharyngeal impression might be visible. Another important factor that might cause a recurrent diverticulum is a weakness of the posterior pharyngeal wall, as shown by van Overbeek et al. [4].

The outcomes of open surgical treatment are very good, and the level of satisfaction following this intervention among patients ranges from 70% to 100% [8, 13, 16].

Open surgical treatment is comparable to the endoscopic approach. Endoscopic management, using the Z-POEM technique, fiberoptic, and rigid endoscopy by applying a stapler, laser, ultrasonic scalpel, or electricity, poses a higher risk of recurrence and retreatment, with no perioperative mortality [14, 15, 17, 23]. The open surgical treatment of diverticula is a method of choice in patients with a recurrent diverticulum following endoscopic failure. Shahawy et al. stated that it should be preferably performed in patients with recurrent pneumonia [12].

Open surgery is one of the primary methods for treating the cervical diverticula of the esophagus. It is becoming less important due to advances in endoscopic techniques that have lower rates of complications-though they, unfortunately, have higher rates of recurrence. The open surgical approach has demonstrated acceptable rates of perioperative complications, high rates of postoperative comfort and has been successfully used in the treatment of older patients.

Author Contributions

Janusz Włodarczyk wrote the first draft; Janusz Włodarczyk and Alicja Włodarczyk contributed discussion and data interpretation; Janusz Włodarczyk and Alicja Włodarczyk redesigned the paper; Janusz Włodarczyk and Alicja Włodarczyk made substantial revisions; Janusz Włodarczyk and Alicja Włodarczyk made statistical analyses; Janusz Włodarczyk and Alicja Włodarczyk reviewed the literature.

Competing Interests

Dr Włodarczyk J and Włodarczyk A have no conflicts of interest or financial ties to disclose.

References

1. Laing MR, Murthy P, Ah-See KW, Cockburn JS. Surgery for pharyngeal pouch: Audit of management with short-and long-term follow-up. *J R Coll Surg Edinburgh*. 1995; 40: 315-318.
2. Ludlow A. A case of obstructed deglutition from a preternatural dilation of and bag formed in the pharynx. *Med Obs Inq*. 1769; 3: 85-101.

3. Zenker FA, von Ziemssen H. Krankheiten des Oesophagus. In: Handbuch der Speciellen Pathologie und Therapie. Leipzig: FCW Vogel; 1877.
4. van Overbeek JJ. Pathogenesis and methods of treatment of Zenker's diverticulum. *Ann Otol Rhinol Laryngol.* 2003; 112: 583-593.
5. Verdonck J, Morton RP. Systematic review on treatment of Zenker's diverticulum. *Eur Arch Oto Rhino L.* 2015; 272: 3095-3107.
6. Aggarwal N, Thota PN. Are there alternatives to surgery for Zenker diverticulum? *Cleve Clin J Med.* 2016; 83: 645-647.
7. Belsey R. Functional disease of the oesophagus. *Postgrad Med J.* 1963; 39: 290-298.
8. Hunter JG, Pellegrini CA. Surgery of the esophagus. In: *Surgical Clinics of North America.* Philadelphia: Saunders Company; 1997.
9. Dindo D, Demartines N, Clavien PA. Classification of surgical complications: A new proposal with evaluation in a cohort of 6336 patients and results of a survey. *Ann Surg.* 2004; 240: 205-213.
10. Rijnhart-de Jong HG, Draaisma WA, Smout AJ, Broeders IA, Gooszen HG. The Visick score: A good measure for the overall effect of antireflux surgery? *Scand J Gastroenterol.* 2008; 43: 787-793.
11. Lang RA, Spelsberg FW, Winter H, Jauch KW, Hüttl TP. Transoral diverticulostomy with a modified Endo-Gia stapler: Results after 4 years of experience. *Surg Endosc.* 2007; 21: 532-536.
12. Shahawy S, Janisiewicz AM, Annino D, Shapiro J. A comparative study of outcomes for endoscopic diverticulotomy versus external diverticulectomy. *Otolaryngol Head Neck Surg.* 2014; 151: 646-651.
13. Gutschow CA, Bauerfeind P. Pharyngoösophageale Divertikel. *Der Chirurg.* 2017; 88: 717-728.
14. Gutschow CA, Hamoir M, Rombaux P, Otte JB, Goncette L, Collard JM. Management of pharyngoesophageal (Zenker's) diverticulum: Which technique? *Ann Thorac Surg.* 2002; 74: 1677-1683.
15. Bonavina L, Bona D, Abraham M, Saino G, Abate E. Long-term results of endosurgical and open surgical approach for Zenker diverticulum. *World J Gastroenterol.* 2007; 13: 2586-2589.
16. Lerut T, Van Raemdonck D, Guelinckx P, Dom R, Geboes K. Zenker's diverticulum: Is a myotomy of the cricopharyngeus useful? How long should it be? *Hepatogastroenterology.* 1992; 39: 127-131.
17. Colombo-Benkman M, Unruh V, Krieglstein C, Senninger N. Cricopharyngeal myotomy in the treatment of Zenker's diverticulum. *J Am Coll Surg.* 2003; 196: 370-377.
18. Kelly JH. Management of upper esophageal sphincter disorders: Indications and complications of myotomy. *Am J Med.* 2000; 108: 43-46.
19. Yuan Y, Zhao YF, Hu Y, Chen LQ. Surgical treatment of Zenker's diverticulum. *Dig Surg.* 2013; 30: 207-218.
20. Crescenzo DG, Trastek VF, Allen MS, Deschamps C, Pairolero PC. Zenker's diverticulum in the elderly: Is operation justified? *Ann Thorac Surg.* 1998; 66: 347-349.
21. Hashiba K, de Paula AL, da Silva JG, Cappellanes CA, Moribe D, Castillo CF, et al. Endoscopic treatment of Zenker's diverticulum. *Gastrointest Endosc.* 1999; 49: 93-97.
22. Payne WS. The treatment of pharyngoesophageal diverticulum: The simple and complex. *Hepatogastroenterology.* 1992; 39: 109-114.
23. Mulder CJ. Zapping Zenker's diverticulum: Gastroscopic treatment. *Can J Gastroenterol.* 1999; 13: 405-407.



Enjoy *OBM Geriatrics* by:

1. [Submitting a manuscript](#)
2. [Joining in volunteer reviewer bank](#)
3. [Joining Editorial Board](#)
4. [Guest editing a special issue](#)

For more details, please visit:

<http://www.lidsen.com/journals/geriatrics>